

Thyrotoxic periodic paralysis: A case report

**Barakat Lafi G. Al Moteri,
Mohammad Aslam**

Department of Medicine, King Saud Hospital,
Post Box No. 1306, Unaizah 51911, Al Qassim,
Saudi Arabia

Address for correspondence:

Mohammad Aslam,
Department of Medicine, King Saud Hospital,
Post Box No. 1306, Unaizah 51911, Al Qassim,
Saudi Arabia. Tel.: +966-550687153.
E-mail: dr.ma007@yahoo.co.in

WEBSITE: ijhs.org.sa

ISSN: 1658-3639

PUBLISHER: Qassim University

ABSTRACT

Thyrotoxic periodic paralysis (TPP) is a rare complication of hyperthyroidism characterized by episodes of muscle weakness and hypokalemia. TPP is typically present in young Asian men, female, and non-Asian ethnic group can also be affected. TPP is a curable cause of hypokalemic periodic paralysis, can often be the first manifestation of thyrotoxicosis. Factors such as high carbohydrate diet, strenuous exercise, emotional stress, and steroid can precipitate an attack of TPP. The presence of both hypokalemia and elevated level of thyroxine (T_4) and triiodothyronine (T_3) are important diagnostic features during the acute episode. Treatment of TPP involves two steps, immediate action to reverse the paralysis by correction of hypokalemia followed by measures to prevent future attacks by restoration of a euthyroid state. We report a first case of TPP, which was delayed to diagnose, from our hospital due to Graves' disease in Asian man who present with second episode of paralytic attack before the diagnosis was made which is also unusual as attacks were not frequent.

Keywords: Graves' disease, hypokalemia, thyrotoxicosis, thyrotoxic periodic paralysis

Introduction

Thyrotoxicosis periodic paralysis (TPP) is acquired disease characterized by triad of acute hypokalemia without total body potassium deficit, muscle paralysis, and thyrotoxicosis.¹ The absence of a family history of paralysis, male sex, presentation in the second to fourth decades of life and sign of thyrotoxicosis help in the diagnosis of TPP.

Case Report

A 28-year-old Filipino gentleman mechanical engineer without any medical problem admitted to our hospital on 16th of February 2016 with complains of numbness and weakness in lower limbs when he woke up for urination at around 3:00 am on the day of admission which started distally symmetrically and progressed proximally and gradually involved the upper limbs in the same pattern, the proximal muscles were affected more severely than distal muscles, became bed bound in over 3 h when he was brought to emergency room (ER) by his roommate. He took large amount of cookies and soft drink at dinner time which triggered this crisis. Past history of weakness of both lower limbs was present in the year 2011 which was recovered fully without any motor sequelae and remained asymptomatic till the day of admission.

On physical examination revealed a healthy male with regular pulse and normal blood pressure with fine tremor on out stretched hands and proptosis of left eye with no palpable goiter. Cardiovascular, pulmonary, and abdominal examinations were unremarkable. The neurological examination revealed cranial

nerves intact with upper and lower limbs power was grade 0/5 and decreased to absent deep tendon reflexes with intact sensation.

In ER initial potassium level was 1.6 mmol/L and electrocardiogram (Figure 1) shows features of hypokalemia, i.e., ST depression, U-wave, and high QRS Voltage. An initial diagnosis of hypokalemia periodic paralysis was kept and intravenous potassium 20 mEq/L along with oral replacement was started following which limb weakness improved in 24 h. His thyroid-stimulating hormone was 0.009 μ IU/L (normal 0.55-4.78), T_4 was 44.2 pmol/L (normal 12-22) and T_3 was 14.9 pmol/L (normal 4.35-6.85), and together with left eye exophthalmos, which were consistent with thyrotoxicosis. Patient was started on propranolol 40 mg BID and Carbimazole 20 mg/day and discharged on the third day with final diagnosis of TPP secondary to Graves' disease.

Discussion

TPP is an uncommon and potentially life-threatening complication of thyrotoxicosis.¹ TPP is common in male Asian descent including Chinese, Japanese, Vietnamese, Filipino, and Koreans and the majority of cases of hyperthyroidism associated with TPP are due to Graves' disease.² The attacks are precipitated by factors such as high carbohydrates diet, strenuous exercise, stress, and corticosteroids.¹

In an acute attack, TPP must be distinguished from other causes of acquired quadriplegia such as familial hypokalemia periodic paralysis, Guillain-Barré syndrome, and proximal myelopathy.³ However, the recurrent attacks with normal

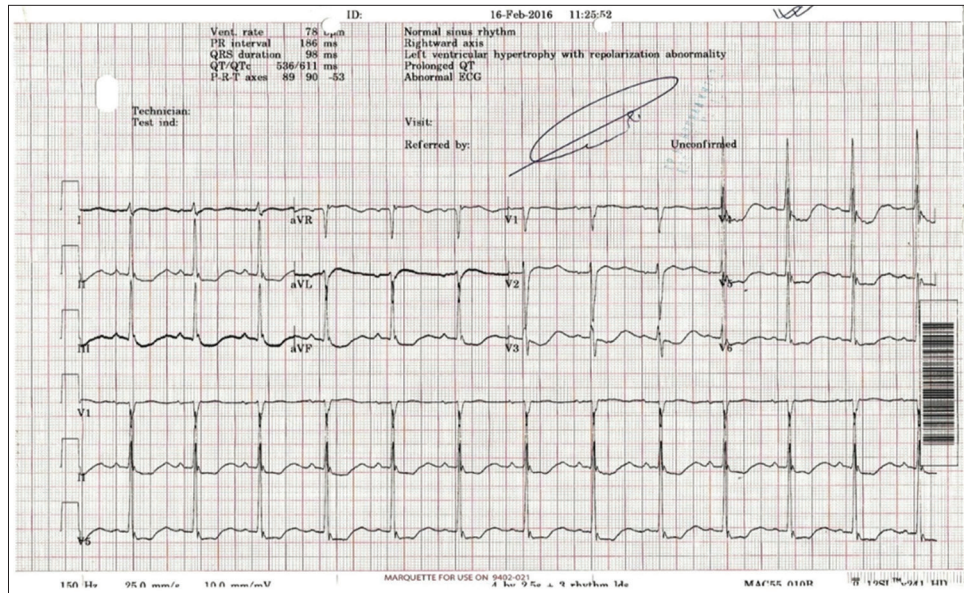


Figure 1: Initial electrocardiogram of the case shows features of hypokalemia, i.e., ST depression, U-wave, and high QRS voltage

plasma potassium levels between attacks distinguish periodic paralysis from other causes of hypokalemic paralysis.

Management

During periodic paralysis and marked hypokalemia immediate supplementation with potassium chloride at slow rate is warranted to prevent major cardiopulmonary complication² and to avoid rebound hyperkalemia. High dose oral propranolol (3-4 mg/kg) alone has been reported to rapidly abort the paralysis.⁴ TPP does not occur once the patient is euthyroid, so adequate control of hyperthyroidism is the mainstay of therapy.

Conclusion

TPP is typically present in young Asian men and can be the first manifestation of thyrotoxicosis and it can present

atypically and likely to be missed initially. Therefore, thyroid function test should be done in all cases of periodic paralysis to make early diagnosis of TPP and to start definitive treatment as it does not occurs once euthyroid is achieved.

References

1. Vijayakumar A, Ashwath G, Thimmappa D. Thyrotoxic periodic paralysis: Clinical challenges. *J Thyroid Res* 2014;2014:649502.
2. Kung AW. Clinical review: Thyrotoxic periodic paralysis: A diagnostic challenge. *J Clin Endocrinol Metab* 2006;91:2490-5.
3. Luiza RR, Magnus RD. Thyrotoxic periodic paralysis-clinical diagnosis and management. In: Soto GD, editor. *Thyroid Disorders-Focus on Hyperthyroidism*. Ch. 6. Rijeka, Croatia: In Tech; 2014.
4. Lin SH, Lin YF. Propranolol rapidly reverses paralysis, hypokalemia, and hypophosphatemia in thyrotoxic periodic paralysis. *Am J Kidney Dis* 2001;37:620-3.