

Correct the smile of a child by neuromuscular facilitation technique: An interesting case report

Vencita Priyanka Aranha¹,
Asir John Samuel¹,
Kanimozhi Narkeesh²

¹Department of Pediatric and Neonatal Physiotherapy, Maharishi Markandeshwar Institute of Physiotherapy and Rehabilitation, Maharishi Markandeshwar University, Mullana, Ambala, Haryana, India, ²Department of Musculoskeletal Physiotherapy, Maharishi Markandeshwar Institute of Physiotherapy and Rehabilitation, Maharishi Markandeshwar University, Mullana, Ambala, Haryana, India

Address for correspondence:

Asir John Samuel,
Department of Pediatric and Neonatal Physiotherapy, Maharishi Markandeshwar Institute of Physiotherapy and Rehabilitation, Maharishi Markandeshwar University, Mullana - 133 207, Haryana, India.
E-mail: asir.j.samuel@gmail.com

WEBSITE: ijhs.org.sa

ISSN: 1658-3639

PUBLISHER: Qassim University

ABSTRACT

Bell's palsy (BP) in children is a rare case with no documented evidence regarding its rehabilitation management. Till date, individuals with BP are being treated with electrical stimulation are proportionately greater than other conventional means such as facial exercise and massage. These conventional modes of treatment have proved to have less incidence of synkinesis with more benefits. Here, we report a case of a 7-year-old boy diagnosed clinically to have right idiopathic facial nerve paralysis, who underwent 14 days of facial proprioceptive neuromuscular facilitation exercises along with facial therapeutic massage. Documented improvements in facial grading system reveal promising outcomes. Hence, we propose the above technique might improve the functional outcome in the children with BP.

Keywords: Bell's palsy, children, exercise, facial paralysis, pediatric rehabilitation, proprioceptive neuromuscular facilitation

Introduction

A complex neuromuscular facial disorder resulting from the paralysis of facial (VII cranial) nerve due to an unknown etiology is termed as idiopathic facial paralysis or Bell's palsy (BP). Although the exact cause of BP is not known, many neurologists believe that recurrence of a dormant viral infection can root the facial nerve to swell and becomes inflamed. Approximately 23% of individual with BP have residual symptoms, such as incomplete motor recovery, synkinesis, hemifacial spasm, and crocodile tears.¹ Most of these sequelae affect the individual both socially and psychologically leading to decline in their quality of life.²

The purpose of this case report is to explain the role of proprioceptive neuromuscular facilitation (PNF) in speeding the recovery in a child diagnosed with BP.

Case Report

The patient is a 7-year-old male child diagnosed with BP of the right idiopathic facial nerve with severe right facial paralysis. He was presented with the left deviation of mouth

angle at rest with incomplete eye closure on the right side, absence of forehead creases, nasolabial fold and typical bell's phenomena with muscle power ranges between non-functional to week functional on the 3rd day from the onset of the above symptoms. To quantify the prognosis, facial grading system (FGS) was calculated.

Goal-directed physiotherapy management used was approach to reduce the edema, prevent the occurrence of synkinesis, and strengthen the muscle and thereby to achieve maximal restoration of facial symmetry (resting/functional). At first, facial massage (stroking, tapping, hacking, kneading (finger/thumb) along with effleurage) was given to drain the edema, improve circulation, prevent contractures, and improve perceptual awareness and then proceeded with the PNF approach-based Kabat concept³ over the left side of the child's face. Facial exercise was performed on the affected side in front of mirror to prevent muscle atrophy and thereby increases muscle function. Sucking cheeks between the teeth, wrapping lips over teeth, making sustained "fff" sound, blowing paper, pronouncing vowels, and expressions such as smiling, snarling, flaring of nose, and raising eyebrows.⁴ The interventions were continued for 14 days. The FGS was recorded every 7th day

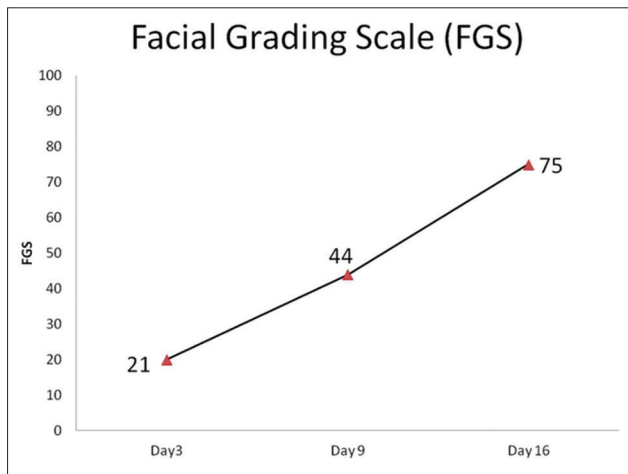


Figure 1: Facial grading system scores of the child with Bell's palsy undergoing proprioceptive neuromuscular facilitation

of treatment to document the recovery (Figure 1). Baseline reading was noted on 3rd day, second reading on 10th day, and final reading on 16th day. Documented reduction in synkinesis was noted.

Discussion

Facial PNF technique helps in stimulating weakened facial muscles by irradiation principle which proved to be better than traditional therapeutic measures for the children with BP like electric stimulation. The child's active participation and visual feedback were also enhancing the recovery. Similar supportive report was documented by Manikandan in adults with BP by a

randomized controlled trial (RCT).⁵ We reported this in a single case as against RCT. Nevertheless, this was the first study to document the effectiveness of PNF in children with BP. Thus, we correct the smile of the child with BP.

Conclusion

Facial PNF along with facial exercise and massage might be an effective rehabilitation approach in rehabilitating the children with BP.

Acknowledgments

We are very grateful for the support provided by Dr. Kanu Goyal, clinical incharge, Maharishi Markandeshwar Institute of Physiotherapy and Rehabilitation, Maharishi Markandeshwar University, for the completion of the case report.

References

1. Valença MM, Valença LP, Lima MC. Idiopathic facial paralysis (Bell's palsy): A study of 180 patients. *Arq Neuropsiquiatr* 2001;59:733-9.
2. Yamamoto E, Nishimura H, Hirono Y. Occurrence of sequelae in Bell's palsy. *Acta Otolaryngol Suppl* 1988;446:93-6.
3. Namura M, Motoyoshi M, Namura Y, Shimizu N. The effects of PNF training on the facial profile. *J Oral Sci* 2008;50:45-51.
4. Brach JS, VanSwearingen JM. Physical therapy for facial paralysis: A tailored treatment approach. *Phys Ther* 1999;79:397-404.
5. Manikandan N. Effect of facial neuromuscular re-education on facial symmetry in patients with Bell's palsy: A randomized controlled trial. *Clin Rehabil* 2007;21:338-43.